

УДК 616.833.58:599.323.4
DOI: 10.24061/1727-0847.19.1.2020.11

R. V. Svyrydyuk

Ukrainian Medical Stomatological Academy, Poltava

MORPHOMETRIC CHARACTERISTICS OF THE SCIATIC NERVE TRUNK STRUCTURAL COMPONENTS WITH A SINGLE INTRODUCTION OF CRYCONSERVED PLACENTA AGAINST THE BACKGROUND OF ACUTE ASEPTIC INFLAMMATION IN RATS

МОРФОМЕТРИЧНА ХАРАКТЕРИСТИКА СТРУКТУРНИХ КОМПОНЕНТІВ СТОВБУРА СІДНИЧНОГО НЕРВА ПРИ ОДНОРАЗОВОМУ ВВЕДЕННІ КРІОКОНСЕРВОВАНОЇ ПЛАЦЕНТИ НА ТЛІ ГОСТРОГО АСЕПТИЧНОГО ЗАПАЛЕННЯ У ЩУРІВ

Резюме. Дослідження проведено на 55 статевозрілих щурах самцях. Показана динаміка змін морфометричних параметрів при одноразовому введенні кріоконсервованої плаценти на тлі гострого асептичного запалення у щурів. Таким чином, доведено, що одноразове введення кріоконсервованої плаценти на тлі гострого асептичного запалення стовбура сідничного нерва, викликане одноразовим внутрішньоочеревинним введенням λ -карагену призвело до загальних змін у стовбурі сідничного нерва максимально на 10-у добу дослідження достовірна різниця ($p > 0,05$) і подальшим достовірним відновленням показника на 21-у добу. Термін 21-а доба після одноразового введення кріоконсервованої плаценти на тлі гострого асептичного запалення сідничного нерва у щурів є достатнім для того, щоб оцінити кінцеві результати регенераторних процесів структури сідничного нерва ушкодженого запальним процесом у щура.

Ключові слова: стовбур, сідничний нерв, кріоконсервована плацента, λ -караген, асептичне запалення регенерація.

At present, the innovative biotechnological methods for treatment of inflammatory processes continue to be experimentally studied. One of such biotechnological methods has been recognized to be the method for inflammatory processes correction by administration the biological origin drugs to rats. Such a drug is cryopreserved placental tissue that activates the compensatory resources of damaged cells and tissues, triggers the regeneration processes, the process of lost tissue cells replacement [1-3].

Inflammation in combination with the metabolic process disorders of varying degrees and neurological symptoms of different etiology is the most typical clinical manifestation that occur with inflammation of the sciatic nerve [4, 5]. One of the main pathophysiological factors of the sciatic nerve inflammation are chronic intoxication, diseases of viral, bacterial origin, generalized infection (purulent inflammations), metabolic disorders, use of food supplements, preservation agents, traumas of different origin (battle traumas), frequent overcooling in military servicemen [1, 2, 6, 7]. Therefore, the clinical symptoms of various chronic diseases in the peripheral nervous system has much in common with diseases of the sciatic nerve trunk, and leads to errors in establishing the correct diagnosis, and in subsequent prognosis for recovery with the nervous peripheral system's inflammation [8-10].

The pathomorphological picture of the inflammatory process in the sciatic nerve is characterized by

signs of inflammation and dystrophic changes in the structural elements of the sciatic nerve trunk and nerve fibers with their subsequent atrophy. The pathological process can be local in nature and it can spread over the entire area along the sciatic nerve trunk's course [1, 4, 6].

It should be taken into account that inflammations of the sciatic nerve trunk often occur in persons of working age, military personnel, and in severe course of the disease they lead to a permanent complete disability. Treatment of this pathology requires some financial expenses, both from the patient and the state, which indicates the socio-economic importance of this problem not only in Ukraine but also abroad [4, 5, 11].

Therefore, an urgent problem of modern experimental medicine is the study of morphometric characteristics of the sciatic nerve trunk's structural components with a single administration of cryopreserved placenta against the background of acute aseptic inflammation in Wistar rats. The study of morphometric manifestations of the disease and the prevalence of damage can be a key to the proper diagnosis and further treatment of inflammatory processes by administering cryopreserved placenta not only into the sciatic nerve trunk, but in the treatment and diagnostics of the peripheral nervous system as a whole.

The purpose of the study was to establish changes in morphometric parameters of the sciatic nerve in rats, with a single administration of cryopreserved

placenta against acute aseptic inflammation in rats.

Object and methods of the study. The object of the experimental study was the sciatic nerve trunk obtained from 55 adult Wistar male rats. The experiment was carried out in compliance with the «Rules for the Use of Laboratory Experimental Animals» (2006, annex 4) and the Declaration of Helsinki on Animal Welfare.

Animals were divided into two groups: Group I (10 animals) – the control; Group II (45 animals) – experimental, including animals who were subcutaneously administered a single fragment of cryopreserved placenta against the simulated acute aseptic inflammation of the sciatic nerve.

Animals were sacrificed by an overdose of thiopental anesthesia according to the established terms (1, 2, 3, 5, 7, 10, 14, 21, 30 days). For light-optical study, the sciatic nerve fragment was taken from animals distal of the middle third of the sciatic nerve, using the above mentioned technique [4]. The collected material was fixed by perfusion in 10 % formalin solution with 0.1 phosphate buffer followed by formalin buffered defixation. Frozen sections 15 μm thick were made by means of MK-25 cryotome. Further slices were impregnated with silver nitrate by a rapid method of modification [6].

Olympus C 3040-ADU digital microscope with photomicrographic attachment was used for the calculations, with software adapted for these studies (Olympus DP-Soft, license No. VJ285302, VT310403, 1AV4U13B26802) and BIOREX 3 (serial number 5604). Mathematical processing of the material was carried out using nonparametric standard methods of variational statistics: calculation of mean values (M), error of the mean (m), Student's t test (t). Differences at $p < 0.05$ were considered reliable.

The work is a fragment of the research project at the Ukrainian Medical Stomatological Academy, MOH of Ukraine «Experimental morphological study on the effect of the cryopreserved cord blood preparations and embryofetoplacental complex (EFPK), diferelin and 1 % ester of methacrylic acid on the morphofunctional status of certain internal organs»,

state registration No. 0119U102925, the author is the co-executor of the present work.

Results of the study and their discussion. The sciatic nerve trunk in rats is represented by the following membranes: connective tissue membrane, which covers directly the trunk of the sciatic nerve – epineurium; longitudinally oriented (collagen, elastic) fibers that act as a septum – perineurium; connective tissue covering bundles of myelin fibers.

When analyzing the morphometric indices of the sciatic nerve trunk's total thickness, it was found that in group II animals, during the experiment, they changed dynamically throughout all terms of the study. The analysis results are presented in fig. 1.

Thus, comparison of the indices between the groups revealed an increase in the total thickness of the sciatic nerve trunk's wall, from the 1st to the 30th day of the experiment. Starting from the 1st day, this parameter significantly increased, with the highest increase on the 7th day. On the 21st day of the experiment, a significant decrease in the total thickness was detected, compared to the similar index of the intact group. On the 30th day, a significant increase in the total thickness of the sciatic nerve trunk was detected.

When comparing the indices of the study terms it was found that there was a significant increase on the first day with a significant increase on the 2nd and 3rd days of the experiment. Further comparison of the indices with each other showed that from the 3rd and 7th day there was no statistical difference revealed. On the 10th day, this index decreased significantly again compared to the 7th day of the study. On the 14th day, this index significantly decreased again compared to the 10th day and on the 21st day it decreased significantly and reached the limits of the control group. On the 30th day of the study, this index was within the control group's limits.

In the statistical analysis of the epineurium thickness between groups during the experiment, the following changes in the epineurium parameters were revealed. The results of the analysis are presented in fig. 2.

The epineurium thickness index varied from the 1st to the 30th day with the maximum increase on the

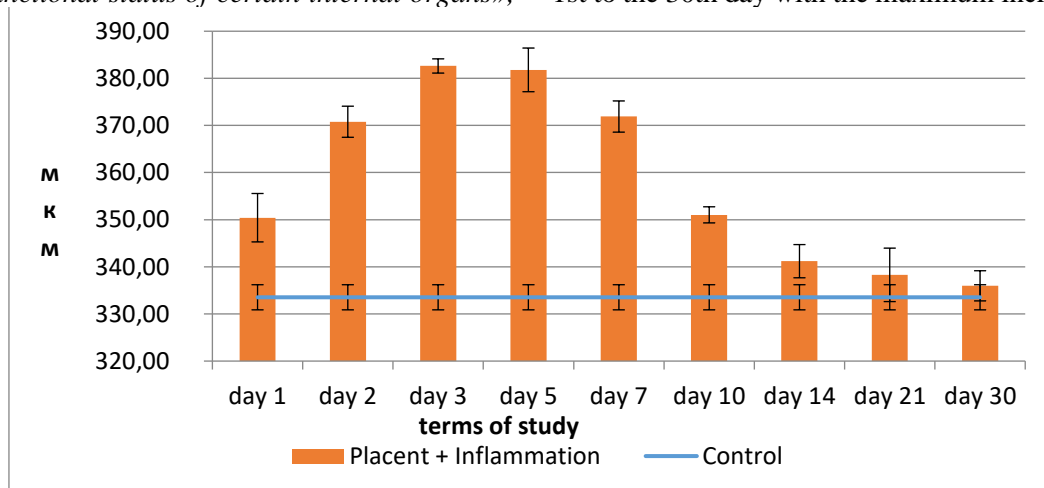


Fig. 1. The total thickness of the sciatic nerve trunk with a single cryopreserved placenta administration against the background of acute aseptic inflammation

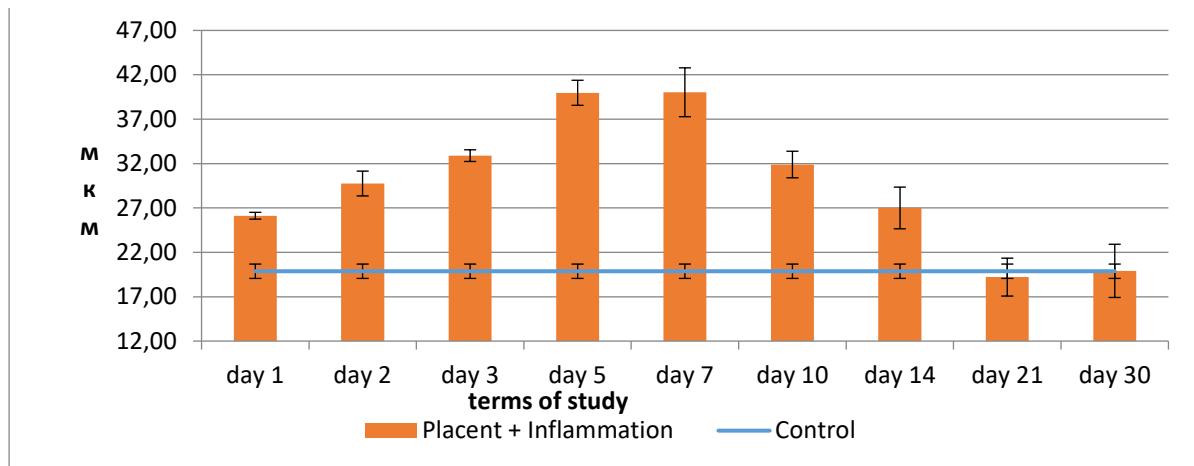


Fig. 2. Thickness of epineurium in the sciatic nerve trunk with a single cryopreserved placenta administration against the background of acute aseptic inflammation

7th day of the study ($p < 0.05$), as shown in fig. 2.

Comparing the epineurium indices between the study periods, a significant increase on the 1st, 2nd, 3rd, 5th days of the study was found with a reliable difference between the terms. Starting from the 7th and up to the 14th day of a significant divergence of values between the terms, a reliable difference was also found ($p > 0.05$). On the 21st - 30th day, the index reliably reached the limits of the control group.

Studying the average values of the perineurium thickness it was found that it also varied unequally during the experiment between the study groups. A significant increase of this index was detected from the 1st day with the maximum value on the 10th day of the experiment. There was a reliable decrease on the 14th-21st day of the study. Morphometric analysis of the perineurium thickness between the study periods (the results of the statistical analysis are presented in fig. 3) showed that from the 1st to the 2nd days there was a reliable increase in this parameter.

On the 3rd - 5th day of the study, the index was still reliably increased, but between the 3rd and the 5th days the growth difference was not reliable. On the 7th day the index grew significantly compared to the values of the 5th day and reached its maximum on the 10th day. The 14th day was characterized by a significant decrease compared to the 10th day. On the

21st day of the study, the perineurium index reached the limits of the control group and maintained within these limits until the 30th day.

The endoneurium also responded to acute aseptic inflammation as it is shown in fig. 4. Statistical analysis between the groups showed that it slightly grew on the 1st day. On the 2nd day, it grew rapidly and reliably, where it maintained until the 5th day of the study. It reached the maximum of 10th day. From the 10th day of the study up to the 30th day it declined rapidly.

Analyzing the indices between the study periods, we found an increase on the 1st day, with a significant increase on the 2nd day where it maintained until the 5th day with a significant increase until the 7th day and maintaining there until the 10th day. Comparing the indices between the study periods from the 10th up to the 14th days, we did not find any significant decrease, with a further drop on the 21st, 30th days.

In general, our findings are consistent with the results obtained by other researchers [1, 2, 4, 7, 12]. The influence of allogeneic transplantation of embryonic nerve tissue on the regeneration of damaged peripheral nerves was studied and its efficacy in the nerve restoration was proved [1]. A number of authors studied and proved the positive effect of cryopreserved placenta on the nerve restoration processes in their

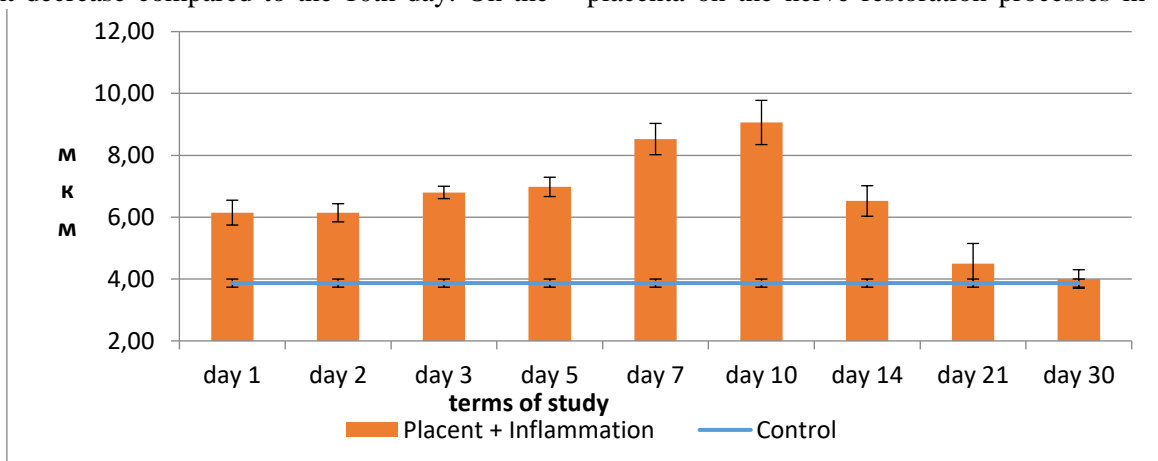


Fig. 3. Thickness of perineurium in the sciatic nerve trunk with a single cryopreserved placenta administration against the background of acute aseptic inflammation

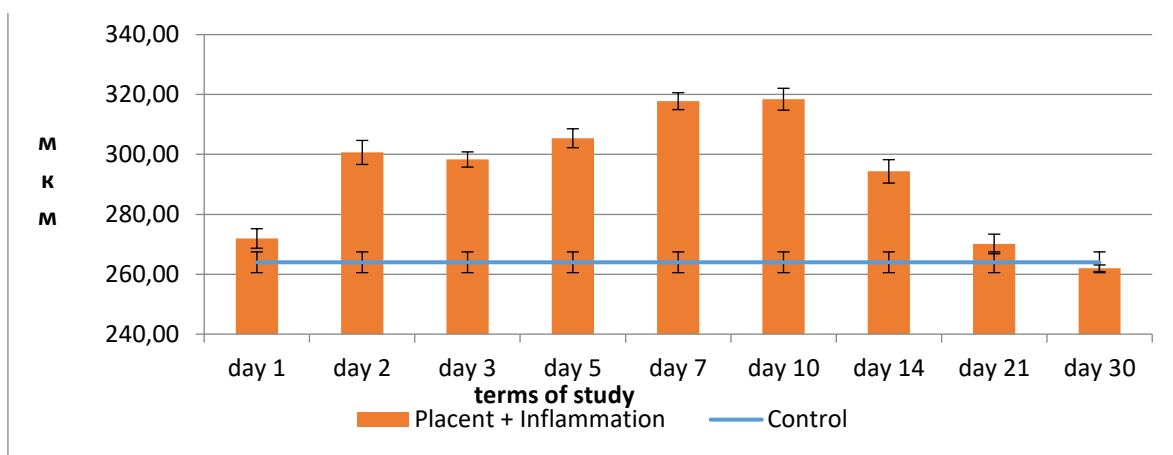


Fig. 4. Thickness of endoneurium in the sciatic nerve trunk with a single cryopreserved placenta administration against the background of acute aseptic inflammation

studies of: current techniques and concepts in peripheral nerve repair [11]; an assessment method for functional recovery after sciatic nerve injury in the rat [5], translational strategies in peripheral neuroinflammation and neurovascular repair [13].

In a rat experiment [2], a comparative histological study of the peripheral nerve regeneration processes was performed 14 days after surgery with end-to-side neural anastomosis and nerve diastasis autoplasty with another nerve. Autotransplantation revealed encasement of the graft with nerve fibers from the proximal end of the damaged nerve. Our study has confirmed the regenerative effect of the cryopreserved placenta and the complete nerve trunk restoration within the period of 21-30 days.

Conclusions. 1. Thus, a single administration of cryopreserved placenta against the background of

acute aseptic inflammation of the sciatic nerve trunk induced by a single intraperitoneal injection of λ -carrageenan led to a total change in the sciatic nerve trunk at its maximum on the 10th day of the study, the difference being reliable ($p > 0.05$) and with further reliable recovery of the index on the 21st day. 2. The term of the 21st day after a single administration of cryopreserved placenta against acute aseptic inflammation of the sciatic nerve in rats is sufficient to assess the final results of regenerative processes in the structure of the sciatic nerve damaged by the inflammatory process.

Prospects for further research. In future, it is planned to study the dynamics of hemomicrocirculatory changes in the sciatic nerve trunk in the normal and with a single administration of cryopreserved placenta.

References:

1. Luzan BM. Vplyv alohennoyi transplantatsiyi embrionalnoyi nervovoyi tkanyny na rehenratsiyu ushkodzhennykh peryferychnykh nerviv [dysertatsiya] [The influence of allogeneic transplantation of embryonic nerve tissue on the regeneration of damaged peripheral nerves]. Kyiv. 2001. 20 s. [in Ukrainian].
2. Lutsik DA, Chaykovskiy YuB. Peregneratsiya perifericheskogo nerva pri nakladyvanii nevralnogo anastomoza konets-v-bok v sravnenii s plastikoy nerva autotransplantatom u krysy [Peripheral nerve regeneration when end-to-side neural anastomosis is applied in comparison with nerve plastic by autograft in rats]. Svit medytsyny ta biolohiyi. 2010;4(27):126-31. [in Russian].
3. Yakushko OS, Shepitko KV. Morfolohichni osoblyvosti perebihu hostroho eksperymentalnoho nevrytu zorovoho nerva shchuriv [Morphological features of the acute experimental optic neuritis course in rats]. Svit medytsyny ta biolohiyi. 2009;4:75-8. [in Ukrainian].
4. Herashchenko S, Deltsova O, Kolomyitsev A, Chaykovskyy Yu. Peryferiyunnyy nerv: neyro-sudynno-desmalni vzayemovidnoshennya v normi ta pry patolohiyi [Peripheral nerve: neuro-vascular-desmal relationships in normal and in pathology]. Ternopil. Ukrmedknyha, 2009. 382 s. [in Ukrainian].
5. Sarikcioglu L, Demirel B, Utuk A. Walking track analysis: an assessment method for functional recovery after sciatic nerve injury in the rat. Folia Morphol. 2009;68(1):1-7.
6. Kolomyitsev A, Chaykovskiy Yu, Tereshchenko T. Bystryy metod impregnatsii serebrom elementov perifericheskoy nervnoy sistemy prigodnyy dlya tselloidinovykh i parafinovykh srezov [A quick method of silver impregnation of peripheral nervous system elements suitable for celloidin and paraffin sections]. Arkhivy anatomii, gistologii i embriologii. 1981;8:93-6. [in Russian].
7. Tsymbalyuk VI, Luzan BM, Tsymbalyuk YaV. Diahnostyka y likuvannya khvorykh iz travmatychnymy ushkodzhennyamy peryferychnykh nerviv v umovakh boyovykh diy [Diagnosis and treatment of patients with traumatic peripheral nerve injuries in combat actions]. Travma. 2015;16(3):13-8. [in Ukrainian].
8. Shepitko KV. Kharakterystyka morfometrychnykh parametriv stinky klubovoyi kyshky pry odnorazovomu vvedenni kriokonservovanoj platsenty ta aseptychnomu zapalenni [Characteristics of the ileum wall morpho-

metric parameters with a single administration of cryopreserved placenta and aseptic inflammation] *Svit medytsyny ta biolohiyi*. 2014;10(46):174-9. [in Ukrainian].

9. Rinkel WD, Huisstede BMA, van der Avoort D-J JC, Coert JH, Hovius SER. What is evidence based in the reconstruction of digital nerves? A systematic review. *Journal of Plastic, Reconstructive & Aesthetic Surgery*. 2013;66:151-64.

10. Stoll G, Joster S, Myers R. Degeneration and regeneration of the peripheral nervous system: From Augustus Waller's observation stone uroinflammation. *Journal of the Peripheral Nervous System*. 2002;7:13-27.

11. Semionow M, Brzezicki G. Current techniques and concepts in peripheral nerve repair. *International Review of Neurobiology*. 2009;87:141-72.

12. Skotarenko TA, Shepitko KV. Reaktsiya kirkovoyi rechovyny nadnyrnykiv pry hostromu aseptychnomu perytoniti ta yoho korektsiyi vvedennyam kriokonservovanoi platsenty [Reaction of the adrenal cortical substance in acute aseptic peritonitis and its correction with administration of cryopreserved placenta]. *Svit medytsyny ta biolohiyi*. 2016;1(55):156-9. [in Ukrainian].

13. Ubogu E. Translational strategies in peripheral neuroinflammation and neurovascular repair. *Transl Neurosci*. 2012;4(3):373-83.

МОРФОМЕТРИЧЕСКАЯ ХАРАКТЕРИСТИКА СТРУКТУРНИХ КОМПОНЕНТІВ СТВОЛА СЕДАЛИЩНОГО НЕРВА ПРИ ОДНОРАЗОВОМ ВВЕДЕННІ КРИОКОНСЕРВИРОВАНОЇ ПЛАЦЕНТИ НА ФОНЕ ОСТРОГО АСЕПТИЧЕСКОГО ВОСПАЛЕНИЯ У КРЫС

Резюме. Исследование проведено на 55 половозрелых самцах крыс. Представлена динамика изменений морфометрических параметров при однократном введении криоконсервированной плаценты на фоне острого асептического воспаления у крыс. Таким образом, доказано, что однократное введение криоконсервированной плаценты на фоне острого асептического воспаления ствола седалищного нерва, вызванное одноразовым внутривентральным введением λ -каррагинана привело к общим изменениям в стволе седалищного нерва максимально на десятый день исследования, достоверная разница ($p > 0,05$) и последующему достоверному восстановлению показателя на двадцать первый день. Срок двадцать один день после однократного введения криоконсервированной плаценты на фоне острого асептического воспаления седалищного нерва у крыс является достаточным для того, чтобы оценить конечные результаты регенеративных процессов структуры седалищного нерва, поврежденного воспалительным процессом у крысы.

Ключевые слова: ствол, седалищный нерв, криоконсервированная плацента, λ -каррагинан, асептическое воспаление, регенерация.

MORPHOMETRIC CHARACTERISTICS OF THE SCIATIC NERVE TRUNK STRUCTURAL COMPONENTS WITH A SINGLE INTRODUCTION OF CRYOPRESERVED PLACENTA AGAINST THE BACKGROUND OF ACUTE ASEPTIC INFLAMMATION IN RATS

Abstract. The study was carried out on 55 adult male rats. The dynamics of changes in morphometric parameters with a single administration of cryopreserved placenta against the background of acute aseptic inflammation in rats is presented. Thus, it was proved that a single administration of cryopreserved placenta against acute aseptic inflammation of the sciatic nerve trunk induced by a single intraperitoneal injection of λ -carrageenan led to a total change in the sciatic nerve trunk that reached its maximum on the 10th day with the reliable difference ($p > 0.05$) and further reliable recovery on the 21st day. The term of 21 days after a single administration of cryopreserved placenta against the background of acute aseptic inflammation of the sciatic nerve in rats is sufficient to assess the final results of regenerative processes in the structure of the sciatic nerve damaged by the inflammatory process in the rat.

Key words: trunk, sciatic nerve, cryopreserved placenta, λ -carrageenan, aseptic inflammation, regeneration.

Відомості про авторів:

Свиридюк Роман Володимирович – аспірант кафедри гістології, цитології та ембріології Української медичної стоматологічної академії, м. Полтава.

Information about author:

Svyrydyuk Roman V. – post-graduate student of the Histology, Cytology and Embryology Department, Ukrainian Medical Stomatological Department, Poltava.

Надійшла 09.01.2020 р.

Рецензент – проф. Хмара Т.В. (Чернівці)